



ISADOR H. LIEBERMAN MD MBA FRCS(C)
Professor of Surgery
the Cleveland Clinic Center for Spine Health
and the Department of Orthopaedic Surgery
9500 Euclid Ave, A41
Cleveland, Ohio, USA. 44195
Office: 216/445-2743
Fax: 216/636 0586

Tuesday, May 01, 2007

TRIP REPORT

Uganda Charitable Spine Surgery Mission, March 19th – March 30th 2007

Team; Isador Lieberman MD, Mark Kayanja MD, Kris Siemionow MD, Ehab Farag MD

Locations; Mbarara Hospital, Mulago Hospital, Mengo Hospital, Katalemwa Cheshire Children's Home

Society Sponsors; Health Volunteers Overseas (Orthopaedic Overseas),
Scoliosis Research Society (Global Outreach Program),

Corporate Sponsors; Medwish Inc, Kyphon Inc, Medtronic Inc, IGN Medical Inc.

Local Physicians; Dr Emanuel Munyarugyero (anaesthesia Mbarara), Dr Stephen Tendo (anaesthesia Mbarara),
Dr Deo Bitariho (orthopaedics Mbarara), Dr Geoffrey Madewo (orthopaedics Mulago),
Dr Fulvio Franchesci (orthopaedics Katalemwa & Mengo)

To whom it may concern,

It is with gratitude and anticipation for the future that I respectfully submit this trip report outlining the accomplishments of our recent Charitable Spine Surgery Mission to Uganda.

I would like to first off acknowledge the support of many who with their contribution allowed us to accomplish more than we had ever anticipated. Medtronic Inc., once again provided sufficient spinal implants and instruments to treat the entire spectrum of spine pathology. IGN Medical Inc., donated a fully refurbished anaesthetic machine which was sorely needed to replace the ("EMO") ether anaesthetic machines still in use at Mulago Hospital. Kyphon Inc., provided Health Volunteers Overseas with a charitable donation that covered travel and shipping related expenses for the team and equipment, as well as patient care related expenses such as the purchase of x-rays, CT scans, analgesic medications and antibiotic medications. Mr Anibal Morales (CCF) found a discarded spinal surgery four-poster frame, and Mr Tony Shawan (CCF) adapted it for us so we were able to safely position patients for major spinal surgery. Dr. John Doyle (CCF) organized the loan of a Glidescope for difficult intubations. Ms Mimi Hable at Medwish was tremendously helpful in sourcing surplus surgical supplies for us to take. Finally, and as always, the staff at HVO especially Maria Trujillo, and the staff at SRS especially Amy Miller, were dedicated and a pleasure to deal with.

By virtue of the above outlined support we were able to tackle any and all spine pathology that presented to us. Our only limitation was time. The prevalence of treatable spine pathology (neglected trauma, acute trauma, spinal infections, spinal tumors, spinal deformity and degenerative conditions) was excessive, and the need for comprehensive spine care, overwhelming.

I would also like to personally thank the members of the team who cared for these patients with selfless abandon. Once again the ever humble Dr Mark Kayanja, was stellar in his organizational efforts. With his boyish charm, Dr Kris Siemionow provided the always needed extra set of hands and was a constant source of comic relief.

Despite his unfamiliarity with the ether anaesthetic machines, Dr Ehab Farag overcame his initial anxiety, and was instrumental in teaching contemporary techniques to the local anaesthesiology staff.

Much like the 2006 visit we journeyed to Uganda not knowing exactly what to expect. The anxiety was intense and the emotions were mixed. On arrival the most notable difference, this year compared to last, was that the Ugandan medical staff, and their patients, knew who we were, when we were arriving, and were eagerly awaiting us. There certainly was no shortage of spinal pathology.

We initiated our clinical activities with a ward round at Mulago hospital. The staff presented to us seven patients, five of whom we agreed needed surgery and two of whom we sent for further workup. Later that same afternoon, we traveled to the Katalamwa Cheshire Children's Home and examined four patients and recommended surgery for one of them, observation for two others and further tests for the fourth. Apparently due to transport issues four patients were unable to get there on time, so we had organized to see them later that week.

Day two took us to the Mulago operating theatre. Here we started with an 8 year old girl who had a rapidly progressive and rigid juvenile scoliosis that measured close to 100 degrees (see figure 1). The plan was for an anterior release and application of traction. This case set the tone for the remainder of the stay. A double thoracotomy (opening the chest) in an 8 year old child can tax even the most sophisticated and best equipped operating room. After trying to sort out monitors and anaesthetic machines we ended up with the ether machine and a manual blood pressure cuff. Somehow we managed to be ultra efficient and thankfully after two hours of surgery all went well.

The next day found us in Mbarara. The drive from Kampala to Mbarara was exactly as bad as I remember. Roads that would make a Hummer shake rattle and even roll. Drivers that would make a demolition derby look tame. The journey brought a whole new meaning to thrill seeking ride. Regardless, we survived the trip to be welcomed by a clinic of well over eighty patients and a ward packed with almost as many (see figures 2 & 3). We ended up evaluating twenty-nine patients and it became obvious we had no chance of operating on even half of those who desperately needed something done. Most likely by benign default, I adopted a first come first served approach. I really struggled with the age old ethical dilemma; who do you pick? After an initial burst of patient evaluations we had decided to start operating that afternoon, yet there were still patients to see us who had traveled across the country for whom we felt obliged to in the least evaluate. As we prepped the operating rooms these patients and their chaperones were shuttled one by one to the operating room corridor, which is in an entirely different building from the clinic, so we could at least give them an opinion.

During surgery that afternoon we resected a tumor from the base of a young girl's neck and decompressed a severely stenotic (nerve compression causing leg weakness) spine in a 44 year old teacher. During the second surgery we lost all electrical power. Eventually we determined that the individual in charge of the emergency generator was away and that the generator did not have any fuel in it. Forty-five minutes later after a moderate amount of not so gentle coaxing, an individual ran out to the petrol station to buy some diesel. Thankfully we were able to resume and complete operating with no untoward issues.

On day four we were back in the operating theatre. Our goals were ambitious. We had three cases prepared for surgery; a 54 year old male with a cervical (neck) fracture dislocation at the C45 level and a right 5th nerve root palsy (grade 2 biceps function), a 55 year old female with presumed multilevel thoracic spine collapse secondary to tuberculosis, and a 60 year old male whose x-ray findings were consistent with myeloma (bone cancer), who needed a tissue biopsy as well as a bone marrow aspirate for diagnostic purposes.

We addressed the cervical fracture dislocation with a posterior exposure to osteotomize (cut the bone) the facets and reduce (realign the bones) the spine followed by an anterior discectomy (removing the damaged disc) and reconstruction. I was astonished at how much we really could do with just a single lateral x-ray of limited quality. I was even more amazed at how well we coped after we once again lost electrical power. As it turned out the

main power never had returned and the generator used up all of the prior days refueling. Despite the situation's best efforts to undermine our treatment, on the very following day this gentleman's biceps function had already improved to grade 3 and his radicular (nerve) pain had resolved.

Once done with the cervical case we tackled the 55 year old female with the presumed tuberculosis. She was already paraplegic and gave us a past history of being treated for tuberculosis. Again all we had was a poor quality lateral x-ray upon which to base our treatment. The initial plan called for a thoracotomy and a multilevel debridement and reconstruction. One must always however remember; it may look like a duck, quack like a duck, even smell like a duck and still turn out to be flamingo. Her T12 collapse just did not fit the story. As we prepared to start I had elected to abandon the thoracotomy for a posterior approach and possibly a costo-transversectomy exposure (exposing the spine from behind after resecting the ribs) for the debridement. As fate would dictate this was a flamingo. On exposure, the tissue and bleeding we encountered pointed to cancer, as opposed to infection. I was deeply troubled by the operative findings, for if I was able to biopsy, or even better, get some form of advanced imaging the whole treatment paradigm would have changed. As we had the tumor tissue exposed, we did take multiple specimens for pathologic analysis, yet a few days later we were informed that she had no money to pay for the processing or interpretation of the specimen. I am satisfied that I made the correct choice to change course and use a posterior approach. In retrospect, I firmly believe she would not have survived a thoracotomy. However, I am disturbed that I put her through an extensive procedure which really had no chance of making her better and as of now still did not provide a treatable diagnosis.

Near the end of the day, I reflected on the lessons learned; 1) trust your instincts, 2) always biopsy, 3) infection rarely skips levels, and 4) just how much you can do in the dark, without suction or cautery, and with a good, sharp Cobb elevator.

Day five was a packing and travel day back to Kampala. As we proceeded to the operating room in the morning to collect our gear there was a line up of patients waiting to be seen (see figure 2). All those we were not able to evaluate the day before. What was I thinking? They would just go back to their respective villages? Dr Mark ended up seeing them as the rest of us packed the equipment and got ready for the spine jolting ride back to Kampala.

Sunday, our sixth day, found us back in Kampala at the Mengo hospital. The only way we were going to complete all the cases we had committed too, was to convince those at the Mengo hospital to let us operate on Sunday. This proves beyond a shadow of a doubt, that no matter where surgeons are in the world, regardless of the day of the week, we are happiest in the operating room. Mark was superb at organizing the surgical nurses and technicians. Even though we compensated them for the effort (that is code for we bribed them away from their families on a Sunday) I am certain, in respect of their "Dr Mark", they would have worked regardless.

Sunday's case proved to be the toughest and most intimidating case we took on. "A.R." was a seven year old child with a smile as wide as the mouth of the Nile river, a three to four year history of spastic paraplegia, and a severe gibbous deformity as crooked as the curves of the Cuyahoga river (see figure 4). He underwent a two level thoracotomy, multiple rib resections/osteotomies (cutting and removing rib segments), thoracic vertebra 6, 7 and 8 debridements, corpectomies (removal of the bone), realignment and reconstructions with the rib grafts. As if this was not enough, it was all followed by posterior fourth through eleventh thoracic vertebrae segmental instrumentation and seventh thoracic level laminectomy and decompression. Once in the chest we were amazed at the complete dissolution of the T6, T7 and T8 vertebrae. As I was laboring through the exposure I could not recall a tougher thoracotomy. The total operative time front and back was over 12 hours. It took every surgical "pearl" I know and even some newly invented ones to get through this case (see figure 5). "A.R." proved to me the absolute resilience of the human spirit. Despite the extensive surgery and an initial stormy post-operative course he always smiled when we saw him. Eventually we determined that he in fact had a gram negative osteomyelitis (that is code for real bad infection) and not tuberculosis so we needed to get him appropriate

antibiotics which the family could in no way afford. He remained spastic after surgery, and only time will tell if he is ever able to walk again. In the least, his effort and ours provided him with a stable straight spine.

Monday took us back to the Mulago operating room. We were now in rhythm as a team. After a coordinated setup and anaesthetic we undertook to reconstruct an L1 (first lumbar vertebra) "burst fracture" (see figure 6). This was performed through a left sided extracavitary approach with L1 corpectomy, reconstruction and stabilization from T12 to L2. The procedure went as smoothly as could be expected, with minimal blood loss. The patient had a left sided lower extremity paresis and right sided lower extremity grade 2 weakness. The following day her right leg strength had improved, the paresis remained static up to our departure.

While we were operating the refurbished anaesthetic machine was delivered to the hospital amidst significant fanfare. Despite not having a pry-bar or screw driver, the local maintenance crew and the delivery team "tore apart" the crate and wheeled the new prized possession into the theatre block (see figure 7).

As we gained confidence and experience we decided to divide the daily responsibilities. Tuesday morning we split the team. Kris went to Mulago to see the patients and get the OR ready, while Mark and I went to Mengo to see the post-op patients. When we returned to Mulago, Kris and Emanuel had our case, a seventeen year old female with idiopathic scoliosis, asleep, positioned and prepped. For her we undertook a posterior segmental instrumentation correction and fusion from T3 to T12. Despite a rigid curve initially and "granite" like bone the correction was substantial (see figure 8).

Again Wednesday we split responsibilities to cover the territory as efficiently as possible. The day's case, lined up for Mengo hospital, was an unfortunate young man who was struck in the back of the neck with a log resulting in C4 C5 C6 complex burst fracture dislocation and a dense C5 (fifth cervical level) paralysis. He had just a flicker of biceps function, weak deltoid function and was in bed for 10 weeks with no traction on a poor mattress resulting in full thickness bedsores (see figure 9). We had set him up in traction prior to our trip to Mbarara so he was stretched out and better reduced by the time we got him to the OR. For him we proceeded with an anterior C5 corpectomy, decompression, reconstruction with iliac crest strut and stabilization with a cervical plate from C4 to C6. We then flipped him for a posterior C4 to C6 lateral mass fusion and stabilization. We achieved an excellent re-alignment. As we had expected, the dura was shredded by the initial injury as we visualized nerve rootlets from behind. To my surprise though, we did not encounter a cerebrospinal fluid leak which I suspect was a reflection of the chronicity of the injury. Even more to my surprise was the dramatic recovery of biceps function the following day. He progressed from a grade 2 flicker to a grade 3 contraction now being able to at least get his hand towards his mouth.

On our final day of surgery at Mulago hospital, confidence dictated that we run two rooms. We had one of the local surgeons, one local anaesthesiologist and two of the residents willing to help as well. In one room we undertook an open biopsy of a presumed infection in a patient with a three month history of T10 level paraplegia. All we had to go on was a poor quality x-ray with a significant peri-vertebral soft tissue shadow extending from T10 to T12. For him we performed a left sided T10 and T11 hemilaminotomy (removal of bone to expose the spinal cord) to explore the epidural space, and extended that into a costo-transversectomy to obtain biopsies of the peri-vertebral soft tissue mass. After all was done the epidural space had some thick granulation tissue, however the peri-vertebral mass looked cancerous.

The bigger case of the day was part two of our girl with the juvenile scoliosis who spent the last seven days in traction (see figure 1). Her post-operative course after the thoracotomy was remarkably easy for her. She tolerated the traction and her family vigilantly had her exercising and doing deep breathing maneuvers. Thankfully the anterior releases and traction provided us with significant correction that we were able to improve upon even more with strategic posterior releases and segmental instrumentation and fusion from T2 to L2. We had used a combination of hooks, sublaminar wires and pedicle screws. We also performed a sixth through tenth rib thoracoplasty (rib removal) to assist in the correction and provide bone graft. During the initial thoracotomy we

strategically osteotomized the ribs but left them in place so upon our return all we had to do was slide them through the periosteal (tissue surrounding bone) sleeves into the midline wound. On completion we were very satisfied with the correction, which we estimated to be down to a 30 degree Cobb angle from close to 100 degrees. Best of all, despite my anxiety, post-operatively, she was neurologically intact. This was one case where I would have relished any form of neurologic monitoring.

Friday in Mulago started with a scoliosis etiology and treatment lecture that I had prepared for the resident staff. The group was attentive but they did not seem to immerse themselves into the session. Most interesting was at the end of the lecture there were no questions, yet every one of them pulled out their memory sticks and asked me for a copy of the slides. Later that day we had the official "handing over" ceremony of the medical equipment and anaesthetic machine. The hospital administration orchestrated a small tour for the media personnel who attended. The speeches were diplomatic and highlighted the plight of health care in Uganda. The appreciation of the administration and medical staff was most sincere.

An absolute highlight of the trip was seeing two of our follow up patients from last year's trip. One was a paraplegic from TB who had undergone an anterior decompression and reconstruction at T12. When she returned to clinic, she walked in with no evidence of myelopathy (spinal cord compromise), and a spectacular smile. The second was a school teacher who we had diagnosed with myeloma, who was also paraplegic (see figure 10). He too underwent an anterior reconstruction. He has recovered enough spinal cord function to walk with a walker and is well underway with his myeloma treatments.

On one hand, for myself and I am certain for the team, providing spine care in Uganda was most gratifying. On the other hand, leaving so many patients uncared for was devastating. The people of Uganda are remarkable. In deference to North Americans they have absolutely no sense of entitlement and do not seem to adhere to any dependant behavior. They are amazingly appreciative of anything you can do. Even something as simple as acknowledgement of their predicament is graciously received and respectfully accepted. I found the people and patients to be spectacularly resilient to social and physical stressors, ably adapting to overcome any obstacles. There was never a question of how to adapt or why to adapt.

The medical staff with whom we had worked, were a pleasure to deal with. It was clear that they were limited in their scope and expertise. This however, does not necessarily translate, under most circumstances, to lack of compassion or care. What may be construed as lack of compassion is a reflection of medicine in Uganda being practiced with a paternalistic approach. This by contemporary North American standards is clearly no longer acceptable. We did interact with a few "pockets" of ambition, particularly some of the medical house staff who were eager to participate and learn.

After the May 2006 mission I debated the merits of these missions. Are we upsetting the balance? Are we introducing false expectations? Are we doing any good? Many have asked me, with so much prevalent pathology do you think you are really making a difference? This year I realize what we are doing is far less than a drop in the ocean. I am however convinced that we are making a difference. My hope is that by helping one, he or she can then help two, they can then help four and soon we shall have a wave.

Respectfully submitted,

Isador Lieberman MD MBA FRCS(C)

Uganda Charitable Spine Surgery Mission Summary

Highlights

- 1) Delivery of all the equipment as planned and only slightly behind schedule
- 2) The hospitality of the professional staff
- 3) The gratitude and affection of the patients and their families
- 4) Follow up from last years patients
- 5) The recognition of the Charitable Spine Surgery Mission by all involved as a vital and sustainable program

Accomplishments

- 1) Donation and delivery of a refurbished anaesthetic machine for exclusive use in the Mulago Hospital Orthopaedic operating theatres
- 2) Donation of adequate spine surgery implants to tackle the most significant spinal reconstruction cases
- 3) Over seventy patients seen in evaluation
- 4) Eleven patients received surgical care over twelve operative sessions with no major complications
- 5) Twelve patients have been triaged for surgery for the next mission, principally paediatric and adolescent idiopathic and congenital scoliosis

Future Goals

- 1) Establish a permanent surgical base
- 2) Establish a quarterly spine team presence
- 3) Contribute to the education mandate of the Mulago hospital orthopaedic training program
- 4) Establish an independent tax exempt charitable foundation to support this mission in perpetuity

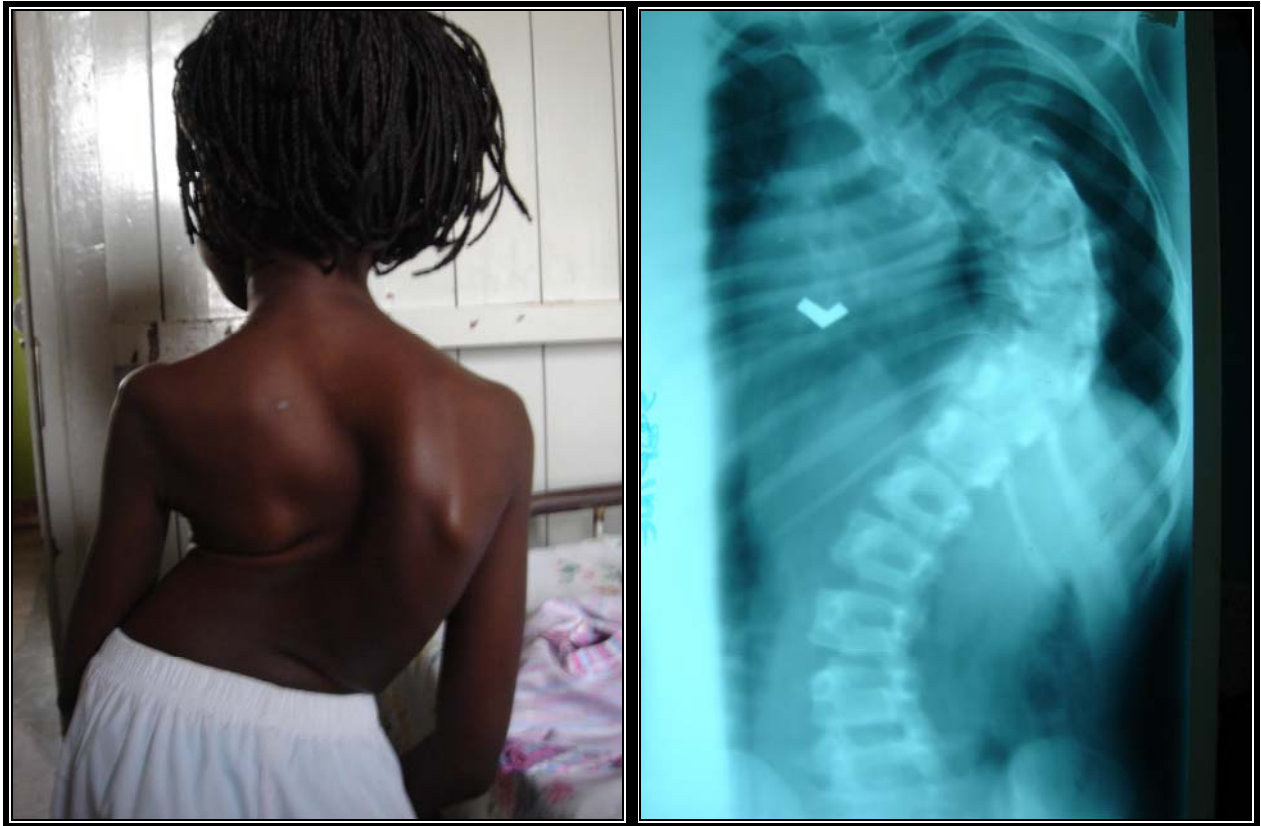


Figure 1, 8 year old girl with juvenile scoliosis



Figure 2, patients waiting to be seen

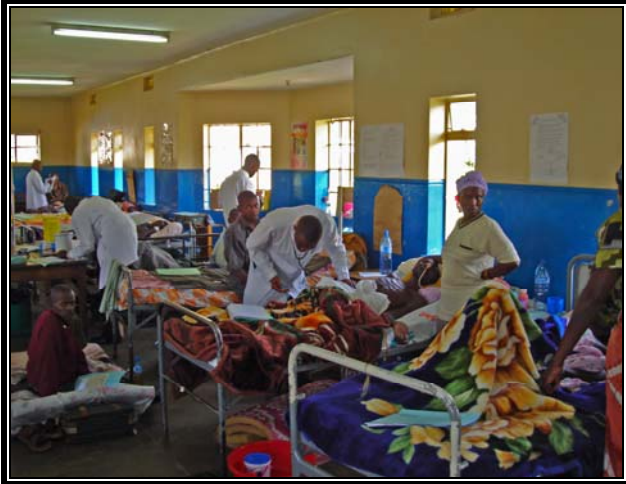

Figure 3, Mbarara Hospital Patient Ward

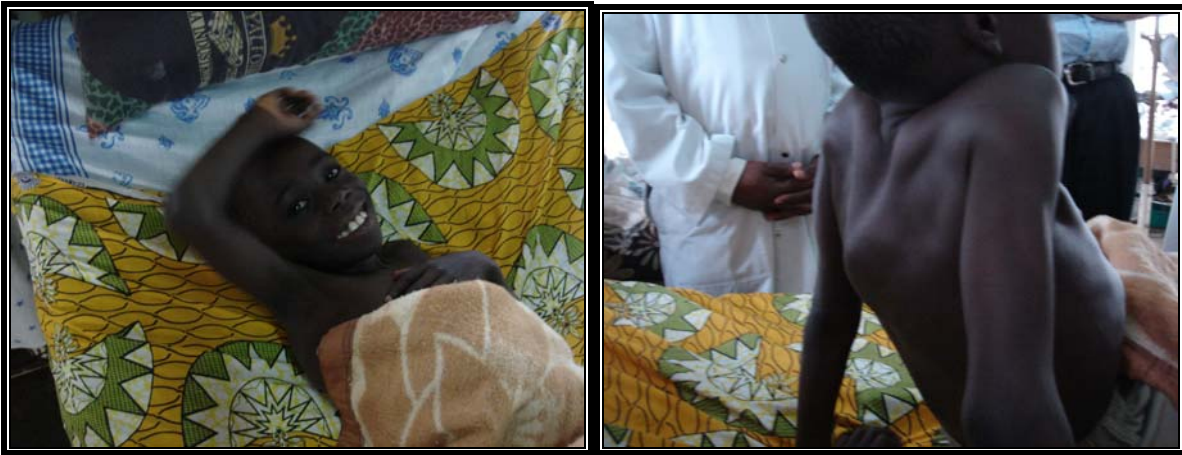

Figure 4, A.R., a smile as wide as the mouth of the Nile, a spine as bent as the curves of the Cuyahoga

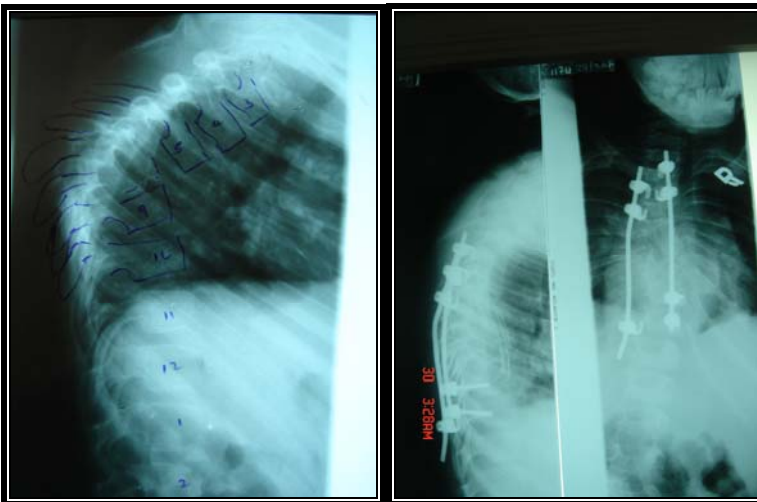


Figure 5, A.R., pre-operative and post-operative x-rays

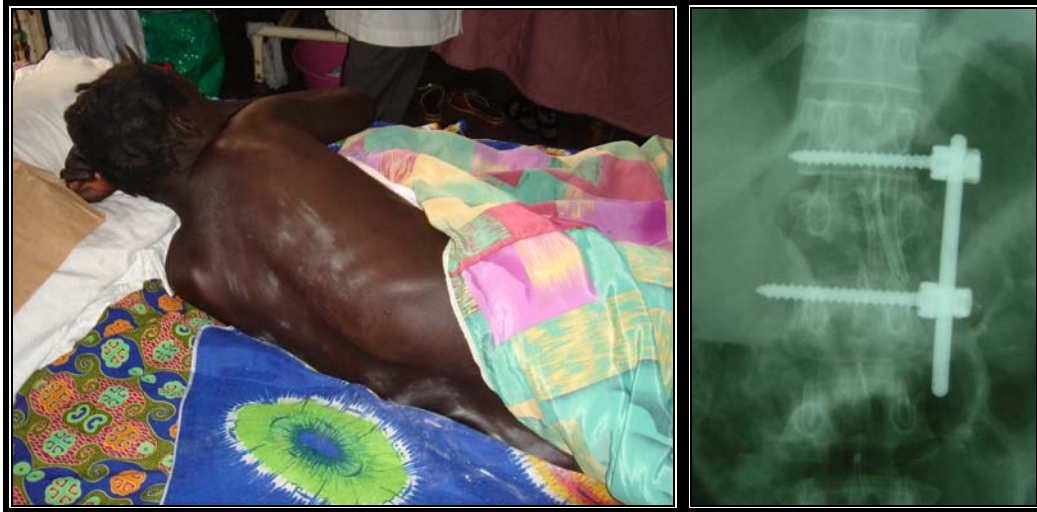

Figure 6, 30 year old female with L1 burst fracture with paraparesis, pre-op condition, post-op x-ray



Figure 7, delivery of anaesthetic machine

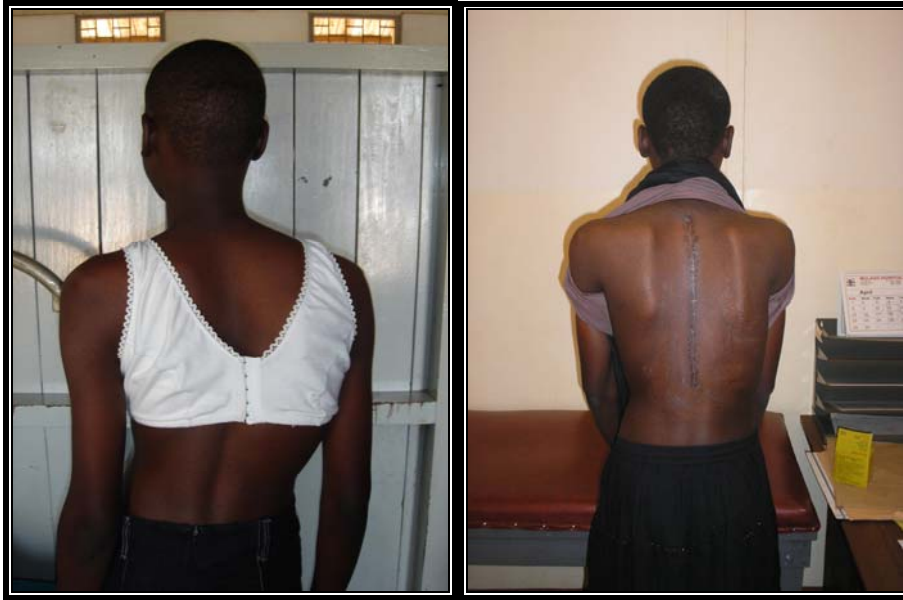

Figure 8, 17 year old female with Idiopathic Scoliosis, pre-op, 2 weeks post-op

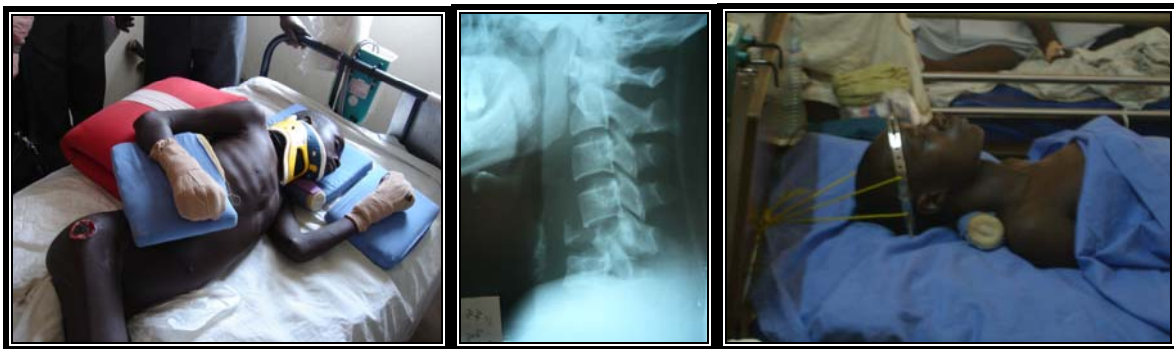

Figure 9, 24 year old male with C4C5C6 complex burst fracture dislocation, note bed sores on hips

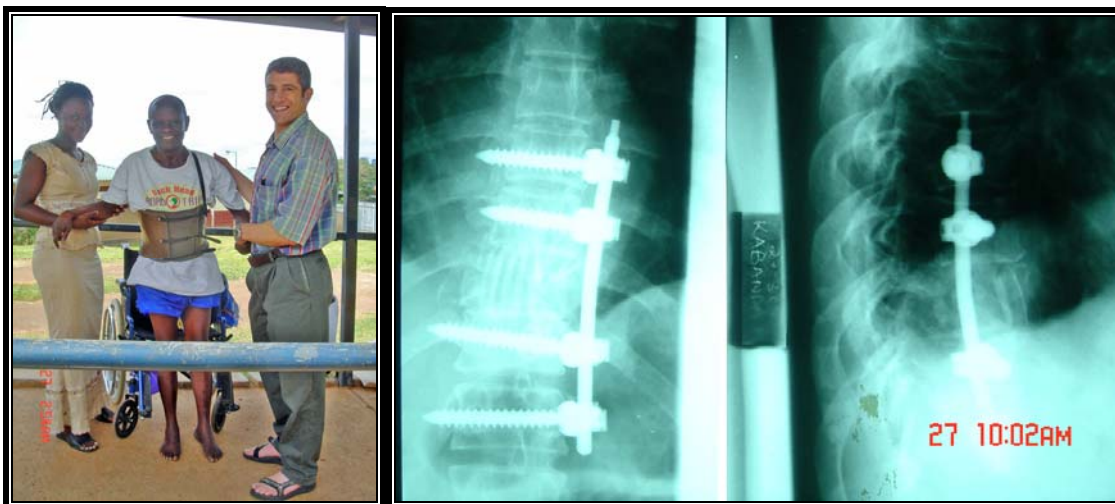

Figure 10, 10 month follow up visit, anterior reconstruction for multiple myeloma, spinal cord function recovered

2007 Patient List

Cat	No	Age	Sex	Appt	Location	Symptoms	Diagnosis	Treatment
OP	1	33	M	20-Mar-07	Old Mulago	3 mo h/o Quadripareisis	Congenital stenosis, ?PID,	CT myelo, ?ACDF
OP	2	22	M	20-Mar-07	Katalemwa	Progressive spastic quadripareisis	Rotatory subluxation C1-C2	VD decomp & fusion
OP	3	32	F	22-Mar-07	Mbarara	Lt foot drop following fall	Motor & sensory weakness Lt L4-5, L5-S1	MRI, AFO & PT
OP	4	39	M	22-Mar-07	Mbarara	Backache	L4-5 disciitis	TB trial, FU 2008
OP	5	14	M	22-Mar-07	Mbarara	Rt th scoli	Flexible Rt th scoli	6 mo FU
OP	6	8mo	F	22-Mar-07	Mbarara	Rt th-lum scoli	FOF Lt T10, accessory Rt L2 & L4	FU 2008
OP	7	50	F	22-Mar-07	Mbarara	Back pain, lt leg radicular	Central & lateral recess stenosis	FU 2008
OP	8	51	F	22-Mar-07	Mbarara	Back pain, Rt radic, pain Rt knee	Rt knee effusion	NSAIDS, aspirate Rt knee
OP	9	53	M	22-Mar-07	Mbarara	Back pain	DDD, psoriatic arthropathy	NSAIDS, PT
OP	10	55	M	22-Mar-07	Mbarara	Back pain, Rt radicular	Multilevel DDD	NSAIDS, PT, FU 2008
OP	11	45	F	22-Mar-07	Mbarara	Back pain	L5-S1 DDD	NSAIDS, PT
OP	12	55	F	22-Mar-07	Mbarara	Back pain	Mechanical back ache	NSAIDS
OP	13	67	M	22-Mar-07	Mbarara	Back pain	L5-S1 DDD	NSAIDS, PT
OP	14	55	F	22-Mar-07	Mbarara	Neck pain following MVA	Normal cervical X-rays and MRI	NSAIDS, PT
OP	15	63	M	22-Mar-07	Mbarara	Back pain, lt LL weakness, walking stick	L3-4, L4-5 & L5-S1 DDD, HIV positive	NSAIDS, PT
OP	16	57	M	22-Mar-07	Mbarara	Movement generated tremor	?Cerebellar lesion	RV by neurologist
OP	17	70	M	22-Mar-07	Mbarara	Quadripareisis LL > UL	Cervical myelopathy w/o spinal compression	RV by neurologist
OP	18	56	F	22-Mar-07	Mbarara	Back pain	Lumbar DDD	NSAIDS, PT
OP	19	66	M	22-Mar-07	Mbarara	Neck & back pain, Rt & Lt LL radicular	Cervical & lumbar DDD, post decomp & fusion	NSAIDS, PT
OP	20	55	M	22-Mar-07	Mbarara	UL pain	Cervical DDD	NSAIDS, PT
OP	21	52	F	22-Mar-07	Mbarara	Neck & knee pain	OA Rt knee	NSAIDS, PT
OP	22	14	F	22-Mar-07	Mbarara	Back deformity	Congenital kyphosis L1, multiple rib fusions	Observe, no Sx, FU 2008
OP	23	7	F	23-Mar-07	Mbarara	Back deformity	Butterfly T12, hemivertebra L1, balanced curve	Annual FU till 11, biannual till 16
OP	24	18	M	23-Mar-07	Mbarara	Neck pain	OM C7, T1, T2 with draining sinus	Bx, Rx
OP	25	47	M	23-Mar-07	Mbarara	Back pain and impotence	Normal lumbar X-rays	RV by urologist
OP	26	32	M	23-Mar-07	Mbarara	Back pain and body ache	Normal lumbar X-rays	NSAIDS
OP	27	40	M	23-Mar-07	Mbarara	Back pain post MVA	Normal lumbar X-rays	NSAIDS
OP	28	36	F	23-Mar-07	Mbarara	Back pain, Rt LL paraesthesia	Mechanical back ache	NSAIDS
OP	29	32	M	23-Mar-07	Mbarara	Back pain	Loss of lumbar lordosis on X-ray	NSAIDS, PT
OP	30	65	M	23-Mar-07	Mbarara	Back pain & inability to walk	?Multiple myeloma, osteoporosis & VCF L1	Admit, Bx, Rx
OP	31	56	M	23-Mar-07	Mbarara	Back pain and reduced ROM	Lumbar DDD	NSAIDS, PT
OP	32	52	F	23-Mar-07	Mbarara	Back pain	Lumbar DDD	NSAIDS, PT
OP	33	50	F	23-Mar-07	Mbarara	Back pain	Lumbar DDD	NSAIDS, PT
OP	34	75	F	23-Mar-07	Mbarara	Back pain	Lumbar DDD	NSAIDS, walking cane, PT
OP	35	9 mo	F	28-Mar-07	Mengo	Failure to move UL & LL	Achondroplasia	FU 2008
OP	36	12	M	28-Mar-07	Mengo	Paraplegia following a fall	paraplegia T4-5, endplate # T5-T10	FU 2008
OP	37	21/2	F	28-Mar-07	Mengo	Spinal curvature	Congenital Rt th scoli, Rt FOF	FU 2008
OP	38	57	M	28-Mar-07	Mengo	Back pain	Post L4-5 decomp for DDD	NSAIDS, PT
OP	39	40	F	28-Mar-07	Mengo	Bilateral LL weakness	Polyneuropathy	Wheelchair, Vit B12
OP	40	52	F	28-Mar-07	Mengo	Back & lower abdominal pain	Post lumbar decomp for DDD	NSAIDS
OP	41	60	F	28-Mar-07	Mengo	Back pain	Post L4-5 fusion	NSAIDS
OP	42	27	F	29-Mar-07	Old Mulago	Leg pain	Tibialised Rt fibula, post Lt girdlestone	OD leg dressing, AFO
OP	43	40	M	29-Mar-07	Old Mulago	Back pain	Post lumbar PID	NSAIDS
OP	44	65	M	29-Mar-07	Old Mulago	Recovering paraplegia, MM	MM Rx, '06 T10 corpectomy & fusion	Train UB, remove catheter, walker

2007 Surgical Cases

Cat	No	Age	Sex	Appt	Location	Symptoms	Diagnosis	Treatment
07SX	1a	8	F	21-Mar-07	Old Mulago	Rt th scolli	Rt rigid th scolli	AR
07SX	2	55	F	22-Mar-07	Mbarara	Back pain, inability to use LL	Spastic paraplegia, mult VCF, osporosis, ?MM	Posterior open Bx
07SX	3	54	M	22-Mar-07	Mbarara	Neck pain & monoplegia from MVA	C4-5 unilateral perched facet	PRIF, ACDF
07SX	4	24	F	22-Mar-07	Mbarara	Neck pain & tumour	Osteochondroma right rib 1	Excision
07SX	5	44	F	22-Mar-07	Mbarara	Back pain & Lt LL radicular	L3-4 and L4-5 stenosis with PID	Posterior decomp
07SX	6	52	M	22-Mar-07	Mbarara	Back pain & LL weakness	VCF T6 & T12, ?MM	PSIS Bx
07SX	1b	8	F	29-Mar-07	Old Mulago	Rt th scolli	Rt rigid th scolli	PRIF
07SX	7	17	F	27-Mar-07	Old Mulago	Rt th scolli	Rt flexible thoracic scoliosis	PRIF
07SX	8	7	M	25-Mar-07	Mengo	Back deformity & paraplegia	TB kyphosis & paraplegia	ARPIF
07SX	9	30	F	26-Mar-07	Old Mulago	Back pain & paraparesis	Burst # L1	ARIF
07SX	10	43	M	29-Mar-07	Old Mulago	Back pain & paraplegia	Tumour T9-T12	Posterior open Bx
07SX	11	24	M	28-Mar-07	Mengo	Neck pain & quadriparesis	C5 burst #, flexion distraction	C5ectomy, C4-6 inst fusion

2008 Surgical Cases

Cat	No	Age	Sex	Appt	Location	Symptoms	Diagnosis	Treatment
08SX	1	15	F	20-Mar-07	Old Mulago	Rt th scolli	L5 weakness, Rt rigid th-lum scolli	ARPIF 2008
08SX	2	17	M	21-Mar-07	Old Mulago	Rt th scolli	Rt rigid th scolli	ARPIF 2008
08SX	3	55	F	22-Mar-07	Mbarara	Back pain, Left LL pain	L3-4, L4-5 stenosis	Decomp L3-4, L4-5 & L5-S1 2008 ARPIF 2008
08SX	4	46	M	22-Mar-07	Mbarara	5 year deformity & paralysis	Kyphotic spine T9-L1	ARPIF 2008
08SX	5	15	F	23-Mar-07	Mbarara	Rt th scolli	Rt flexible th scolli	PIF 2008
08SX	6	10	M	22-Mar-07	Mbarara	Back pain & deformity	TB spine T9-L1	ARPIF 2008
08SX	7	10	F	22-Mar-07	Mbarara	Spinal TB & deformity	Rigid TB kyphosis	ARPIF 2008
08SX	8	63	M	22-Mar-07	Mbarara	Back & neck pain	L3-4, L5-S1 central stenosis	Lumbar decomp 2008 ARPIF 2008
08SX	9	16	F	22-Mar-07	Mbarara	Rt th scolli, intrin hand & LL weakness	NM scolli, ?Freidrich's ataxia	ARPIF 2008
08SX	10	16	F	28-Mar-07	Mengo	Rt spinal curve	Rt rigid th scolli	ARPIF 2008
08SX	11	12	F	28-Mar-07	Mengo	Paraplegia following TB	TB kyphosis with paraplegia	ARPIF 2008
08SX	12	18	M	20-Mar-07	Katalemwa	Progressive back curvature	Post polio scolli, knees & Lt shoulder	T2-L4 PIF 2008